

The Anterior Cruciate Ligament

Kevin Michael Kaplan, MD
Sports Medicine, Joint Replacement
SAN MARCO



One of the most common injuries I see in my office is a tear of the anterior cruciate ligament (ACL). Most of these injuries occur during a rapid change in direction, landing from a jump, pivoting, or from contact to the knee during activities like being tackled during football. Other high-risk sports include soccer, skiing, and basketball¹.

Most patients describe the sensation or the sound of a pop in the knee followed by difficulty ambulating and swelling. In addition, patients may describe the feeling of instability or buckling in the knee after tearing an ACL.

So what is the ACL and why is it so important to an active patient? The anterior cruciate ligament connects the femur (thigh bone) to the tibia (shin bone) (figure one). It is one of four main ligaments providing stability to the knee joint. The ACL prevents excessive forward motion of the tibia in relation to the femur. It also prevents excessive rotation of the knee joint.

By examining the knee, I can evaluate the ACL in addition to the other ligaments and cartilage in the knee. The Lachman test and anterior drawer test are the two best exams for determining the integrity of the ACL.

In order to obtain a definitive diagnosis, patients are sent for an MRI (magnetic resonance imaging). An MRI evaluates the soft tissue structures and will provide information about the cartilage and ligaments in the knee (Figure two).

Unfortunately, given the fact that the ACL is located within the knee joint and is surrounded by joint fluid, it does not have the ability to heal once it's torn. The options after being diagnosed with an ACL tear are conservative management with bracing the knee in combination with rehabilitation or operative management with an ACL reconstruction. Nonoperative

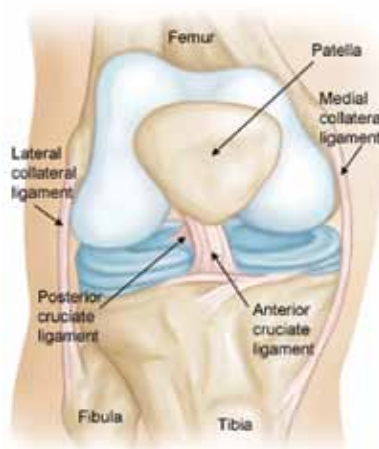


Figure one: Anatomy of the knee

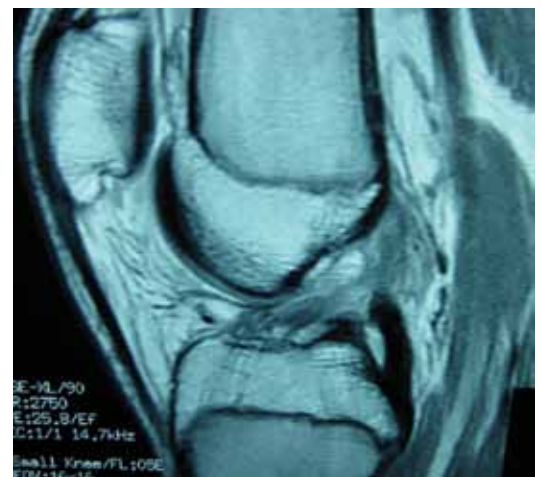

Figure two: MRI – ACL tear

treatment is reserved for individuals who do not have symptoms of instability and do not plan on returning to high-level activities.

In active, healthy patients with the desire to continue activities requiring cutting and pivoting, my recommendation is to reconstruct the ACL². Reconstructing the ACL involves substituting a tendon in the location of the patient's original ligament. This tendon then becomes the new ligament over a period of several months. The tendons used for reconstruction can be obtained from the patient (autograft) or can be obtained from cadaveric tissue (allograft).

Recent orthopaedic studies have shown greater than 20% failure rates when using allograft in patients younger than 25³. Thus, in my practice, I strongly recommend autograft in this patient demographic. Patients older than 25 are given the options to have autograft versus allograft after a thorough discussion of all of the potential risks, benefits, and alternatives.

The two most commonly utilized autografts include the patellar tendon and the hamstring tendon. Both have shown similar high success rates in returning patients to an active lifestyle. Potential issues with patellar tendon autografts include

the risk of anterior knee pain while potential issues with the use of hamstring tendons include the risk of decreased flexion strength. Commonly used allografts include the patellar tendon, achilles tendon, and the hamstring tendon.

Regardless of graft choice, ACL reconstruction is done on an outpatient basis and typically takes one to two hours to perform depending on if there is any other concomitant cartilage injury in the knee. With the aid of a camera and through small incisions in the skin, the new ACL is placed into the knee through tunnels in the femur and tibia and metal or bioabsorbable screws stabilize the graft in these tunnels (Figure three – five).

Rehabilitation begins immediately with a focus on obtaining full knee extension and working on strengthening the muscles surrounding the knee. Patients are placed into an extension brace and utilize crutches for support in the early postoperative period. The process of the new graft becoming a ligament takes several months to occur. During this period of ligamentization, the patient will be working on range of motion, strength, and agility training. Typically, running doesn't begin until 4 months postoperative and a clearance to full sport occurs at 9 months.

I would like to finish up by answering common questions that I hear in my office in regard to ACL reconstructions. What is the success rate of this operation? The rate of success in creating a stable knee is between 85-90%. Over the last 10 years, we have focused on a more anatomic reconstruction of the ACL in attempts to decrease any potential failures. Can I re-tear my ACL? The new ACL (if allowed to gain it's full strength over the rehabilitation period) can tear again, but should be at as much of a risk to tear as your native ACL. Am I going to get arthritis in the future? There is a chance given the injury and also if there is meniscus or cartilage damage at the time of injury that the knee may get arthritis in the future, but this is unpredictable. How can I put myself at risk for a re-tear after the surgery? Most patients feel comfortable and pain free after the first few months. However, what we know biologically is that the ACL graft does not incorporate and become a new ligament for quite some time. Trying to rush back to sports is one of the main reasons why athletes sustain early re-tears.

ACL injuries are devastating to both professional and recreational athletes. However, surgical reconstruction of this important stabilizing ligament has a high rate of success in allowing patients to return to their desired sport.

1. Griffin LY. Noncontact Anterior Cruciate Ligament Injuries: Risk Factors and Prevention Strategies. *J Am Acad Orthop Surg* 2000;8:141-150.

2. Johnson RJ, Beynon BD, Nichols CE, et al. Current concepts review. The treatment of injuries of the anterior cruciate ligament. *J Bone Joint Surg Am* 1992;74A:140-151.

3. Sun K, Tian S, Zhang J, Xia C, Zhang C, Yu T. Anterior cruciate ligament reconstruction with BPTB autograft, irradiated versus non-irradiated allograft: a prospective randomized clinical study. *Knee Surg Sports Traumatol Arthrosc* 2009;17(5):464-74.

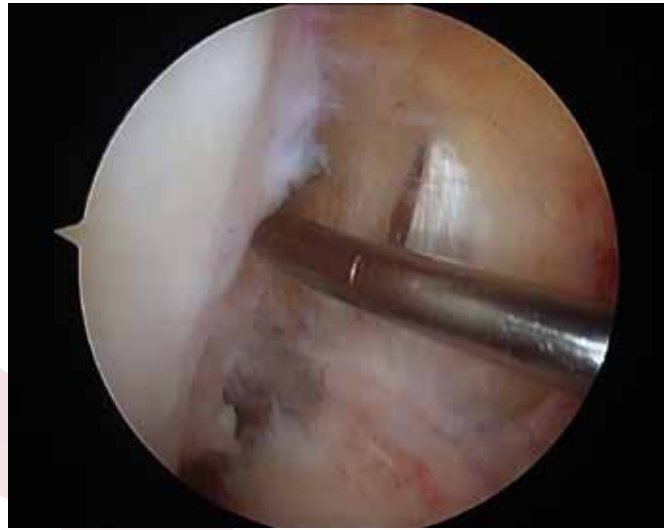

Figure three: Arthroscopic photo – ACL tear – “empty notch”

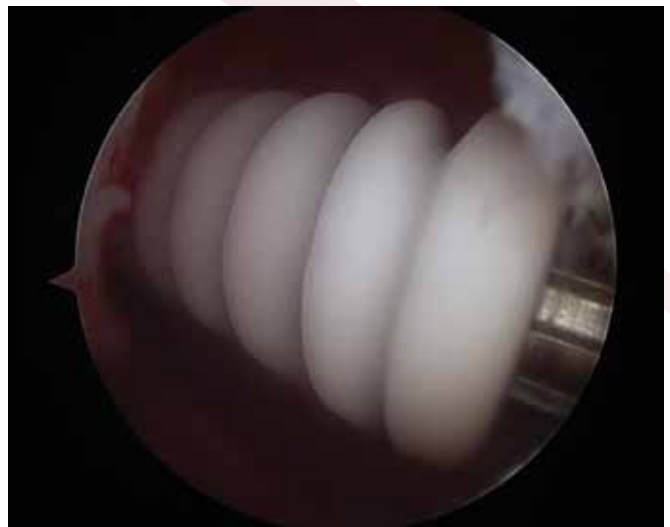

Figure four: Bioabsorbable screw for ACL fixation

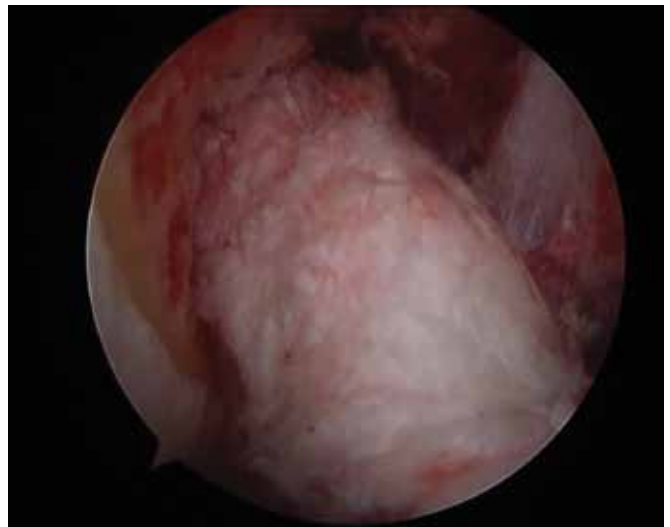

Figure five: ACL reconstruction